

ORIGINAL ARTICLE

Laser skin resurfacing with a novel portable erbium:YAG laser

KHALIL A. KHATRI¹, JAMES GORDON² & LALITHA GARMELA¹

¹Skin & Laser Surgery Center of New England, Nashua, NH and Chelmsford, MA, USA, and ²Westchester Eye Associates, White Plains, NY, USA

Abstract

Background and objective. The erbium:YAG laser is a popular modality for laser skin resurfacing (LSR). This study was performed to evaluate the safety and efficacy of a new portable Er:YAG laser in the treatment of photo-damaged skin.

Methods. Nine patients with skin types I–III were treated for rhytides, large pores, pigmented lesions, lentiginos and photo-damage. Small facial areas such as the periorbital area, nose, cheeks, and upper lip were treated with one to six passes at 5–6 J/cm² with a new portable Er:YAG laser. Topical and local anesthesia was used.

Results. All treated areas showed improvement and, depending upon the number of passes, re-epithelialization was complete within 2–7 days. The intense erythema resolved within 7 days and there was blending of treated and untreated areas within 2 weeks.

Conclusion. The technique of applying a tailored number of 5–6 J/cm², 300 μs pulses of a new portable Er:YAG laser to small areas appears to be safe and effective. There was minimal discomfort and a high level of patient satisfaction after a relatively short recovery time.

Key words: Laser resurfacing, Erbium, YAG laser, Portability

Introduction

The desire to look young and attractive is as old as human history. The advancement of laser technology has brought cosmetic procedure to the forefront and the number of cosmetic procedures is increasing every year. The introduction of CO₂ laser skin resurfacing (LSR) and its media coverage has brought laser terminology into common usage. LSR first with the CO₂ laser and then with the erbium:YAG laser gave dramatic improvement in signs of aging, but one of the undesirable effects is the slow and long recovery. In today's fast-moving world our patients demand quick treatments with no or minimal downtime. We as physicians and researchers developed new technologies and techniques which brought 'non-ablative' treatments to our patients. Despite advancements in non-ablative technology, we still believe that ablative LSR provides the most dramatic clinical improvement in wrinkles and photo-damaged skin (1). LSR essentially produces controlled thermal injury to the dermis. It is the process of wound healing with the production of new collagen in response to the injury that leads to the improvement of wrinkles (2).

In 1997, the Er:YAG laser received FDA approval and since then it has been a popular alternative modality to the CO₂ laser for LSR. The Er:YAG laser has been proven to have comparable efficacy with the CO₂ laser with fewer side effects and a faster recovery time (3). Furthermore, the Er:YAG laser with a wavelength of 2.94 μm has an absorption level in water 16 times greater than that of the CO₂ laser (4). This property makes it an ideal tool for tissue ablation, and hence improvement of facial rhytides. To minimize the recovery time and lower the risk of complications, many of us have developed 'superficial' ablative techniques, where only one pass with the CO₂ laser or a few passes with low fluence of the Er:YAG laser are used. This study attempted to evaluate the efficacy and safety of a new portable Er:YAG laser using relatively low fluence to treat signs of photo-damage.

Materials and methods

Nine female patients were recruited from an outpatient clinic for this study. All volunteers signed consent prior to participating in the study. Four

Correspondence: Khalil A. Khatri, Skin & Laser Surgery Center of New England, 74 Allds Street, Nashua, NH, USA. Fax: 1 603 594 2585. E-mail: skinlaser@aol.com

(Received 16 July 2005; accepted 30 November 2005)

patients had type I skin, four had type II and one had type III skin. The youngest patient was 26 years and the oldest was 63 years, with a mean age of 47 years. The patients had varying degrees of photo-damage and all patients were photographed prior to the treatments.

Er:YAG laser (FriendlyLight[®], FriendlyLight Laser Corp., Tarrytown, NY, USA; Figure 1) treatments were performed in the periorbital, nose, cheek and upper lip areas. Anesthesia was achieved with either topical EMLA[®] cream (AstraZeneca LP, Wilmington, DE, USA) if the number of passes was three or fewer, or intradermal injection of 2% lidocaine with epinephrine if the number of passes was more than three. A fluence of 5–6 J/cm² was used with a 300 μ s pulse, a spot size of 6 mm and a repetition rate of 1.5–2.0 Hz. Depending upon the degree of photo-damage, three to seven passes were used to treat the area. All personnel used safety goggles and patients' eyes were covered with wet gauze. All patients were asked to apply Aquaphor[®] ointment (Beiersdorf Inc., Wilton, CT, USA) to keep the treated area moist.

Patients returned for follow-up visits at 1 week, 2 weeks and 3 and 6 months after the treatment. Patients were photographed before, and 7 and 14 days after treatment. Patients completed a questionnaire and reported their level of satisfaction at 3 and/or 6 months after the treatment.

Results

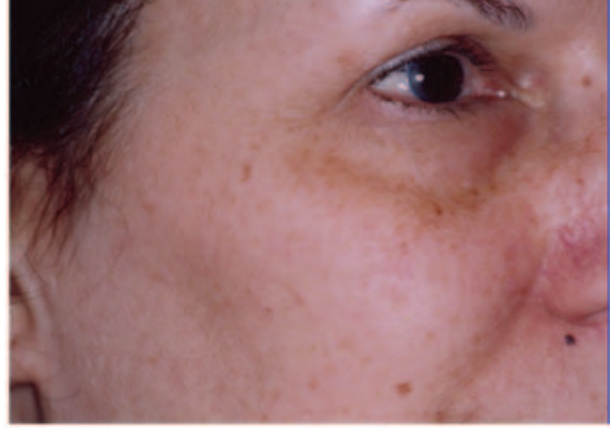
The technique of applying a tailored number of 5–6 J/cm² 300 μ s pulses of this portable Er:YAG laser to small areas appears to be safe and effective. The re-epithelialization was complete in 2–7 days depending upon the number of passes. The average duration of intense erythema was 7 days. The blending of the treated and untreated areas in terms of skin color and texture was evident in less than 2 weeks. The patients reported mild to moderate discomfort and the level of satisfaction was reported to be high. (Figures 2–3.)



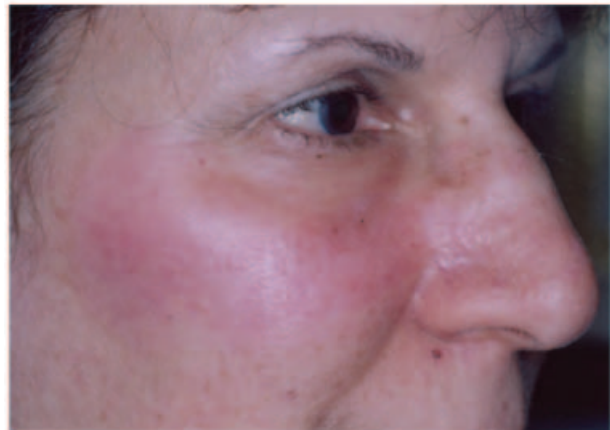Figure 1. FriendlyLight[®] Er:YAG laser.

Discussion

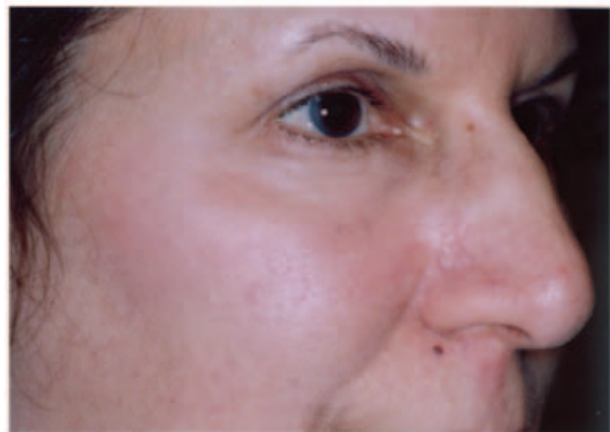The use of lasers for resurfacing skin has revolutionized the approach to treatment of wrinkles and other signs of photo-damage in the last decade. The Er:YAG laser has not only been proven to be an



(A)

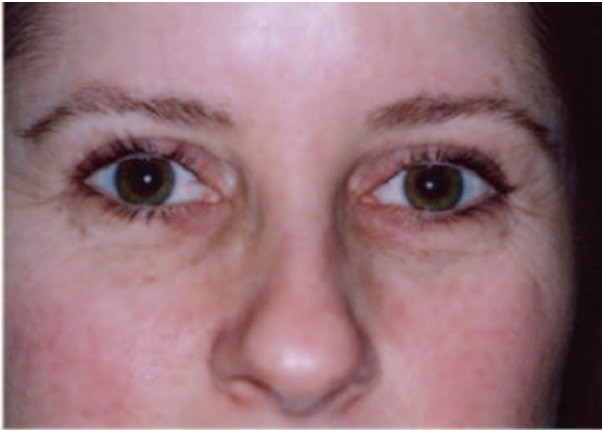

(B)

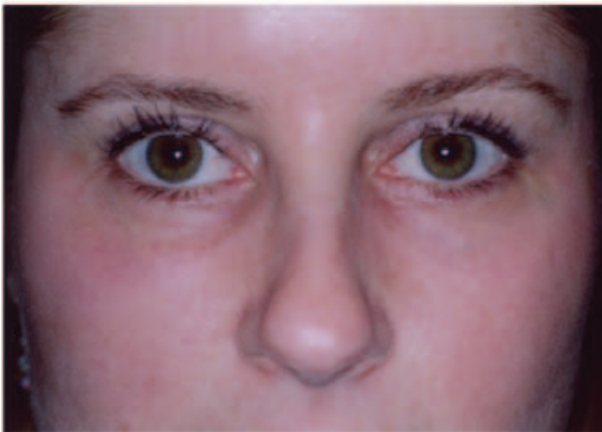

(C)

Figure 2. (A) Before, and (B) 7 days and (C) 14 days after treatment: five passes, 5 J/cm², 6 mm spot, 1.5 Hz.



(A)



(B)

Figure 3. (A) Before and (B) 9 days after treatment: four passes, 5 J/cm², 6 mm spot, 1.5 Hz.

efficacious modality for LSR (5) but also for the removal/ablation of various cutaneous lesions (6–10). Furthermore, compared with the CO₂ laser, the Er:YAG laser has a shorter downtime and a lesser risk of complications (3).

The Er:YAG laser has been proven to be a better option for darker skin types because of a lower risk of post-treatment pigmentation problems, a common complication seen with darker skin after ablative laser treatment (11–13).

A superficial skin ablation with an Er:YAG laser is a useful method for treating the effects of photoaging. As the Er:YAG laser is very effective in ablation of skin, it can be used for deep tissue ablation to

remove dermal benign lesions and can also be used to treat superficial and deep rhytides. The operator can control the depth of ablation and use it to remove superficial lesions such as solar lentigines, actinic keratoses and deep class III rhytides in severely photo-damaged skin.

This study shows that a new portable device, the FriendlyLight Er:YAG laser, can be used effectively to treat various aspects of photoaging. Many physicians are maintaining multiple practices and cannot afford to have multiple sets of laser devices at each location. As we move towards new laser technologies, we desire more effective devices with fewer or no side effects and devices that are financially affordable and are small enough in size not to take up too much space in the operating room. The device we tested is unique in its ability to be effective and still small and portable.

References

1. Alster TS. Cutaneous resurfacing with CO₂ and erbium:YAG lasers – preoperative, intraoperative and postoperative considerations. *Plast Reconstr Surg.* 1999;103:619–32.
2. Fitzpatrick RE, Goldman MP, Satur N, Tope W. Pulsed carbon dioxide laser resurfacing of photo aged facial skin. *Arch Dermatol.* 1996;132:395–402.
3. Khatri KA, Ross V, Grevelink JM, Magro CM, Anderson RR. Comparison of erbium:YAG and CO₂ lasers in resurfacing of facial rhytides. *Arch Dermatol.* 1999;135:391–7.
4. Walsh JT, Deutsch TF. Er:YAG laser ablation of tissue: measurement of ablation rates. *Lasers Surg Med.* 1989;9:327–33.
5. Fleming D. Controversies in skin resurfacing. The role of erbium. *J Cutan Laser Ther.* 1999;1:15–21.
6. Kaufman R, Hibst R. Pulsed erbium:YAG laser ablation in cutaneous surgery. *Lasers Surg Med.* 1996;19:324–30.
7. Beier C, Kaufman R. Efficacy of erbium:YAG laser ablation in Darier disease and Hailey-Hailey disease. *Arch Dermatol.* 1999;135:423–7.
8. Jacob CI, Dover JS. Birt-Hogg Dube syndrome: Treatment of cutaneous manifestations with laser skin resurfacing. *Arch Dermatol.* 2001;45:98–9.
9. Alora MB, Arndt KA. Treatment of café-au-lait macule with the erbium:YAG laser. *Arch Dermatol.* 2001;45:566–8.
10. Ammirati CT, Giancola JM, Hruza GJ. Adult-onset facial colloid millium successfully treated with the long-pulsed Er:YAG laser. *Dermatol Surg.* 2002;28:215–19.
11. Sriprachya-Anunt S, Marchell NL, Fitzpatrick RE. Facial resurfacing in patients with Fitzpatrick skin type IV. *Lasers Surg Med.* 2002;30:86–92.
12. Polniforn N, Goldberg DJ, Suwachinda A, Ng SW. Erbium:YAG laser resurfacing in Asians. *Dermatol Surg.* 2000;24:1303–7.
13. Lodhi A, Huzaira M, Khatri K. Erbium:YAG laser skin resurfacing: A Pakistani experience. *J Cosmet Laser Ther.* 2003;5:43–7.