

This article was downloaded by: [Khatri M D, Khalil]

On: 20 February 2009

Access details: Access Details: [subscription number 908870505]

Publisher Informa Healthcare

Informa Ltd Registered in England and Wales Registered Number: 1072954 Registered office: Mortimer House, 37-41 Mortimer Street, London W1T 3JH, UK



Journal of Cosmetic and Laser Therapy

Publication details, including instructions for authors and subscription information:

<http://www.informaworld.com/smpp/title~content=t713399564>

Efficacy and safety of a 0.65 millisecond pulsed portable ND:YAG laser for hair removal

Khalil A. Khatri ^a; Robert A. Lee ^b; Lynne J. Goldberg ^c; Beejul Khatri ^a; Veronica Garcia ^a

^a Skin & Laser Surgery Center of New England, MA and Nashua, NH, USA ^b Department of Dermatology, University of Pennsylvania, Philadelphia, PA, USA ^c Section of Dermatopathology, Department of Dermatology, Boston University Medical Center, Boston, MA, USA

First Published: March 2009

To cite this Article Khatri, Khalil A., Lee, Robert A., Goldberg, Lynne J., Khatri, Beejul and Garcia, Veronica (2009) 'Efficacy and safety of a 0.65 millisecond pulsed portable ND:YAG laser for hair removal', *Journal of Cosmetic and Laser Therapy*, 11:1, 19 — 24

To link to this Article: DOI: 10.1080/14764170802612976

URL: <http://dx.doi.org/10.1080/14764170802612976>

PLEASE SCROLL DOWN FOR ARTICLE

Full terms and conditions of use: <http://www.informaworld.com/terms-and-conditions-of-access.pdf>

This article may be used for research, teaching and private study purposes. Any substantial or systematic reproduction, re-distribution, re-selling, loan or sub-licensing, systematic supply or distribution in any form to anyone is expressly forbidden.

The publisher does not give any warranty express or implied or make any representation that the contents will be complete or accurate or up to date. The accuracy of any instructions, formulae and drug doses should be independently verified with primary sources. The publisher shall not be liable for any loss, actions, claims, proceedings, demand or costs or damages whatsoever or howsoever caused arising directly or indirectly in connection with or arising out of the use of this material.

ORIGINAL ARTICLE

Efficacy and safety of a 0.65 millisecond pulsed portable Nd:YAG laser for hair removal

KHALIL A. KHATRI¹, ROBERT A. LEE², LYNNE J. GOLDBERG³, BEEJUL KHATRI¹ & VERONICA GARCIA¹

¹Skin & Laser Surgery Center of New England, Chelmsford, MA and Nashua, NH, USA, ²Department of Dermatology, University of Pennsylvania, Philadelphia, PA, USA and ³Section of Dermatopathology, Department of Dermatology, Boston University Medical Center, Boston, MA, USA

Abstract

Background and objective: Based upon the thermal relaxation time of the hair follicle (10–50 ms), most lasers and light devices use relatively long pulse widths for hair removal. This study was conducted to evaluate a shorter pulsed, 0.65 ms Nd:YAG laser for hair removal. **Methods:** One half of each axilla of six female participants was treated and the other half was monitored as a control. The treatment sites were treated with a fluence of either 21 J/cm² or 36 J/cm² using an Nd:YAG laser with a wavelength of 1064 nm and a pulse duration of 0.65 ms. A manual hair count was done before treatment and at each follow-up visit. **Results:** Four months after four monthly treatments, the hair reduction was graded as 5 (75–100% reduction) on the high fluence side and 4 on the low fluence side (50–75% reduction) by individuals and investigators. The average hair count 4 months after four treatments in the sites treated with a high fluence went from 114 to 28 (76% reduction) and in the low fluence areas from 135 to 38 (72% reduction). **Conclusion:** This well-controlled study shows that a 0.65 ms Nd:YAG laser is effective and safe for hair removal.

Key words: Hair removal, lasers and light sources, short pulse

Background and objective

The desire to remove unwanted hair is universal and laser and light-based hair removal is one of the most popular and fastest growing cosmetic procedures around the world (1). There are many ways to temporarily remove hair such as bleaching, shaving, plucking, waxing and chemical depilatories (2). Electrolysis offers more permanent hair removal but the procedure is tedious, time-consuming and painful. The search for ‘permanent hair eradication’ continues. Permanent hair removal is defined by the US Food & Drug Administration (FDA) as: “... the long-term, stable reduction in the number of hairs re-growing after a treatment regime, which may include several sessions. The number of re-growing hairs must be stable over time greater than the duration of the complete growth cycle of hair

follicles, which varies from 4 to 12 months according to body location. Permanent hair reduction does not necessarily imply the elimination of all hairs in the treatment area” (3).

Laser/light hair removal (LHR) treatments lead to a significant reduction in the number of terminal hairs. These treatments are easy, quick and relatively pain free. The need and popularity of these procedures has created a number of non-dermatologists performing these treatments that include physicians and non-physicians. Currently, devices in use for LHR are the ruby laser (694 nm), alexandrite laser (755 nm), diode laser (800+ nm), and neodymium:yttrium-aluminum-garnet (Nd:YAG) laser (1064 nm) and intense pulsed light (IPL) (590–1200 nm).

The energy from the laser and light selectively targets hair follicles based on the theory of selective photothermolysis (4). Melanin in the hair shaft and

hair follicle acts as the target chromophore, absorbing the energy from laser/light devices. The heat diffuses from hair shaft to hair follicle to peripheral stem cells based on the extended theory of selective photothermolysis, thus destroying the hair follicle (5).

Hair follicles are destroyed by three mechanisms: thermal (through localized heating), mechanical (through shock waves or violent cavitation), and photo-chemical (through generation of toxic mediators such as singlet oxygen or free radicals) (6).

The appropriate wavelength, pulse duration and fluence are chosen to optimize the results of LHR while minimizing possible side effects. A very high fluence and a very long pulse can cause excessive heat damage which can lead to permanent scarring (7). To obtain the spatial confinement of the thermal damage and minimize the potential side effects, the pulse duration must be shorter or equal to the thermal relaxation time (TRT) of the hair follicle, which is estimated to be between 10 ms and 50 ms (8–10). Most laser hair removal devices currently available use a long millisecond pulse for LHR. The Nd:YAG is better suited for hair removal in individuals with dark skin because of its longer wavelength (1064 nm). Most LHR devices are also used after application of cooling gel or lotion and pre-cooling of skin is required to avoid epidermal damage.

This study was conducted to evaluate the safety and efficacy of a novel portable, small, and relatively inexpensive Nd:YAG laser with a short pulse of a microsecond without using a cooling method.

Materials and methods

Individuals were recruited from a dermatology and laser clinic. Six females with an average age of 31 years (16–52 years), five with skin type V and one with skin type III, were enrolled. Four individuals had black and two had brown hair. The hair density was medium for five individuals and light for one; hair thickness was medium for five individuals and thin for one. The procedure, expected results, and possible complications were discussed with each participant in detail and with one parent in the case of a minor individual. A consent form was signed by five adult participants and the parent of the minor participant.

Participants were instructed not to remove hair in the axillae by any method for at least 1 week before treatment and each follow-up visit. Photographs were taken using a digital camera (Cannon Power Shot S2 IS, 5.0 mega pixels) before treatment and at each follow-up visit. Participants were asked to raise

their arms to expose the axillae while lying in a supine position in an examination table. All photographs were taken by the same person in the same room and under the same lighting. Each axilla was divided into two equal halves and labeled using a red marker. One half of each axilla was treated and other half was monitored as a ‘control’. A manual hair count was done at each treatment and control site before treatment and at each follow-up visit. The same individual counted each site at each visit. Standard safety measures were taken during the laser exposure, including but not limited to use of wavelength-specific eyewear by the participants, treating physician and all other personnel present in the treatment room.

The treatment site in each axilla was treated with a fluence of either 21 J/cm² or 36 J/cm². A higher fluence was used with a focused 5 mm spot and a lower fluence was used with a collimated 6 mm spot. No cooling, gel or lotion was used before, during or after the treatment. A portable (18 × 34.5 × 47.2 cm; 22 lbs/10 kg) Nd:YAG laser, LightPod NeoTM (Aerolase, Tarrytown, NY, USA), with a wavelength of 1064 nm and a fixed pulse duration of 0.65 ms was used. The selection of higher and lower fluence was randomized in a way that if the superior half of the right axilla was treated with the higher fluence then the inferior half of the left axilla was treated with the lower fluence. Also, if the superior half of left axilla of participant number one received a higher fluence than the superior half of the left axilla of subject number two received lower fluence. Immediately after the treatment, patients were asked whether the treatment had been tolerable in terms of pain, discomfort and burning on a scale of 1–5. Observations were recorded for erythema, edema, burning and blistering after treatment. Participants were asked whether they had any discomfort or problems at home after treatment. They were also asked to grade the overall hair reduction at each follow-up visit on a scale of 1 to 5, where 1=no reduction, 2=<25%, 3=25–50%, 4=50–75% and 5=75–100%. Investigators also graded the overall hair reduction on the same scale of 1 to 5.

Biopsies were performed to analyze microscopic changes to the hair follicles after treatment. Punch biopsies were performed on the treatment sides on two individuals immediately and 1 week after the first treatment, and 1 month after four treatments. The biopsy sites were cleansed with alcohol swabs and injected with 1 cc of 2% lidocaine with epinephrine. A 4 mm punch biopsy was done followed by 4–0 nylon sutures, which were removed 2 weeks later.

Results

All participants described pain as ‘tolerable’. However, the average pain score during the treatment was 2.9, including both fluences. Only one participant reported discomfort lasting for 2 hours after the first treatment on both sides. There was only faint erythema and mild perifollicular edema during some treatment sessions. None of the participants experienced hyperpigmentation, hypopigmentation, burns, vesiculation, infection or scarring.

One month after 4 monthly treatments, the hair reduction was graded as 5 (75–100%) by individuals and investigators. The average hair count 1 month after four treatments in the high fluence treated sites went from 114 to 18 (84% reduction) and in the low fluence areas from 135 to 24 (82% reduction). Four months after four monthly treatments, the hair reduction was graded as 5 (75–100) on the high fluence side and 4 on the low fluence side (50–75%) by individuals and investigators. The average hair count 4 months after four treatments in the high fluence treated sites went from 114 to 28 (76% reduction) and in the low fluence areas from 135 to 38 (72% reduction), see Figures 1–3 and Table I.

Participants were asked about their level of satisfaction from the treatment on a scale of 1–5, where 1=extremely dissatisfied and 5=extremely satisfied. One participant graded her level of satisfaction as 2, two as 3 and three individuals graded it as 4 (Figure 6). When asked whether they would treat other areas and recommend this procedure to other family members and friends, all but one participant said that they would do it again and would recommend to others.

Clinical examples/photographs are shown in Figures 4–6 with treated and untreated sites, 1 and 4 months after the fourth treatment.

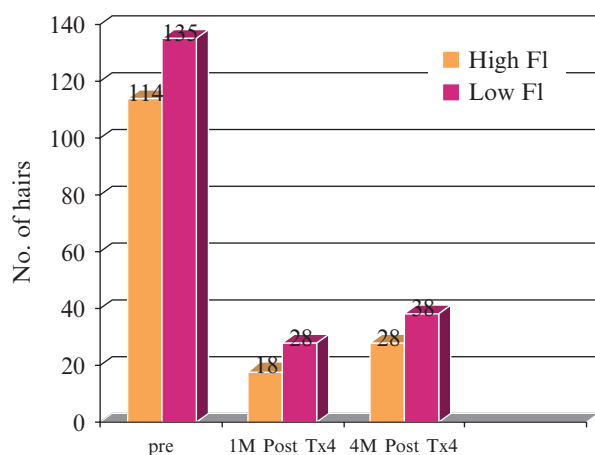


Figure 1. Reduction in hair count.

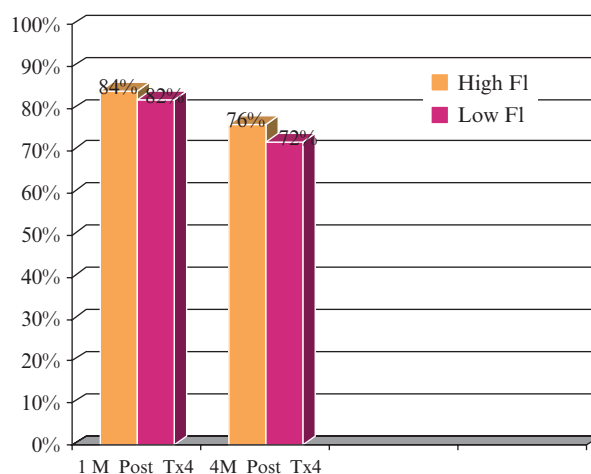


Figure 2. Percentage reduction in hair count.

The histologic evaluation of the representative biopsy sites immediately post-treatment showed fragmentation of the hair shafts, pallor of the spinous layer keratinocytes and elongation of the basal layer keratinocytes. A sparse superficial perivascular lymphocytic infiltrate was seen. These findings are consistent with acute thermal injury to the skin. One week after treatment, acellular debris could be seen focally in the stratum corneum. There appeared to be an increase in the number of melanophages in the reticular dermis. At 4 weeks after the fourth treatment, mild perifollicular fibrosis could be seen as well as trichostasis and trichomalacia. Dermal melanophages again could be seen. Analyses of horizontal sections reveal an increased number of miniaturized hairs compared to control skin. No scarring was observed (Figures 7–10).

These findings are consistent with previous reports describing the histologic findings of laser-mediated hair removal, which include coagulated hair shafts, trichomalacia, pigment incontinence, follicular miniaturization, an increase in the telogen:anagen ratio, and variable amounts of inflammation (11–15). A reduction of the number of

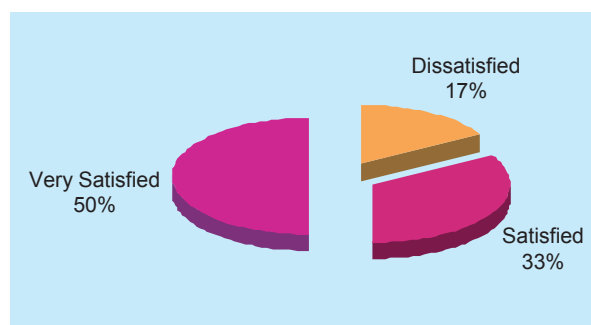


Figure 3. Percentage of individuals satisfied with the procedure (n=6).

Table I. Mean hair count 1 and 4 months after treatment no. 4, all individuals combined.

	High fluence	Low fluence	% Hair reduction
Pre-treatment	114	135	84% (high fluence)
1 month post-treatment	18	24	82% (low fluence)
4 months post-treatment	28	38	76% (high fluence) 72% (low fluence)
Control side pre-treatment	136	113	36% (high fluence)
Control side 1 month post-treatment	87	92	19% (low fluence)
Control side 4 months post-treatment	87	90	36% (high fluence) 20% (low fluence)

follicular units has also been described (12). Because the density of axillary hair is relatively low (compared to scalp) and the tissue samples small, quantification of the number of hair follicles and cycle proved difficult. We did note telogen hair follicles in treated skin, but their number was not appreciably different from control sites.

Discussion

The use of laser and light-based devices to remove unwanted hair is one of the most desired and popular cosmetic procedures around the world (1). Even with the use of the modern state-of-the-art technology that we have available today, we are still searching for

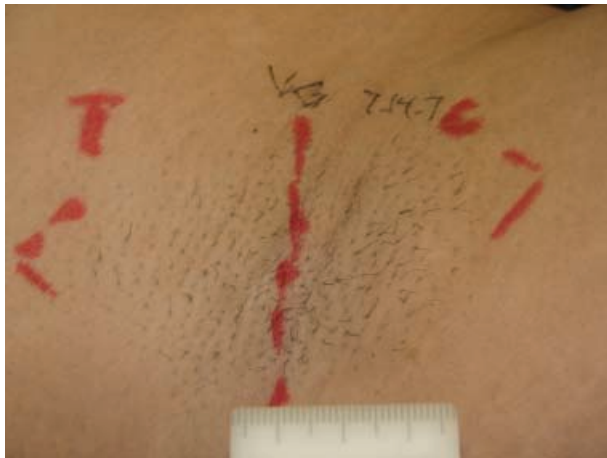


Figure 4. Axilla of individual LD, treatment and control sides, before treatment.

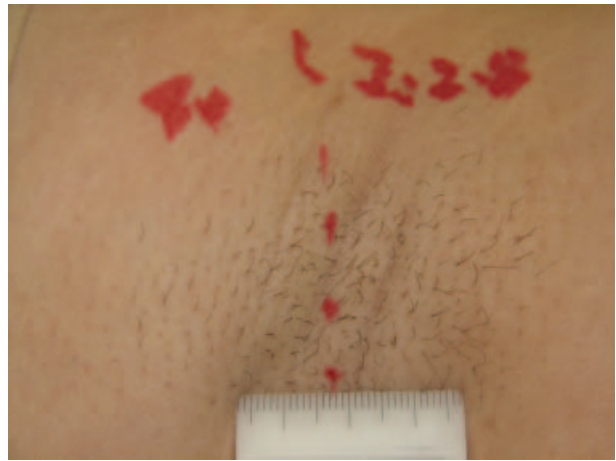


Figure 6. Axilla of individual LD, treatment and control sides, 4 months after four treatments.

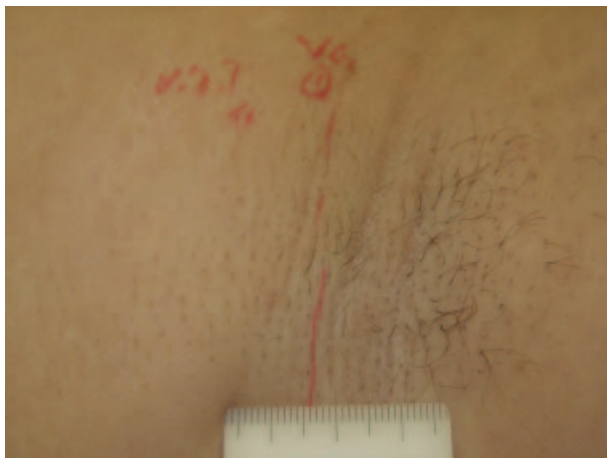


Figure 5. Axilla of individual LD, treatment and control sides, 1 month after four treatments.

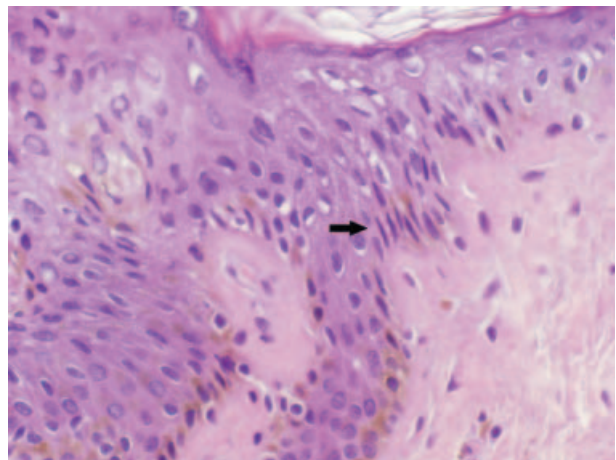


Figure 7. Biopsy immediately post-treatment. Notice pallor of the upper epidermis, and elongated basal keratinocytes (arrow).

Downloaded By: [Khatri M D, Khalil] At: 21:33 20 February 2009

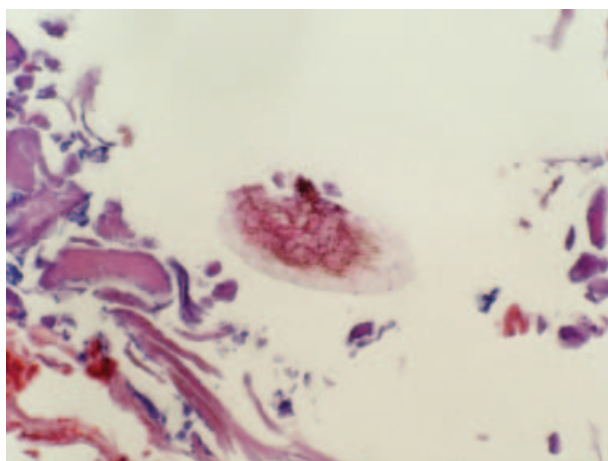


Figure 8. Biopsy immediately post-treatment. The hair shaft at the specimen surface, exhibiting near complete destruction.

'permanent hair eradication'. Any procedure can achieve 'permanent hair reduction' if it decreases the number of re-growing hairs and this decrease in re-growth is stable for a period of 4–12 months. In this study, the participants were followed for 4 months after four monthly treatments to assess the 'permanent hair reduction' as defined by the US FDA.

The new laser/light-based treatments for hair removal result in a significant reduction in the number of terminal hairs in all body areas. LHR was first performed only by dermatologists but a huge demand all around the world for treatments and the relative ease of its use and safety have led to

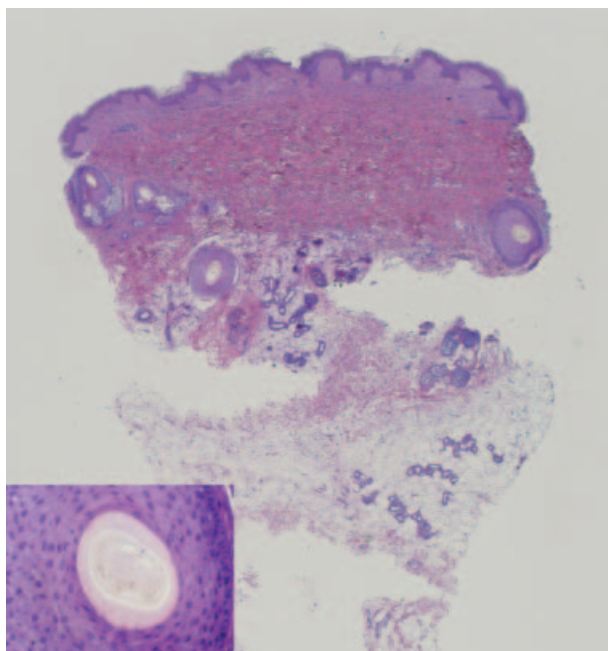


Figure 9. Biopsy pre-treatment. Higher power of a normal sized hair shaft in lower left corner.

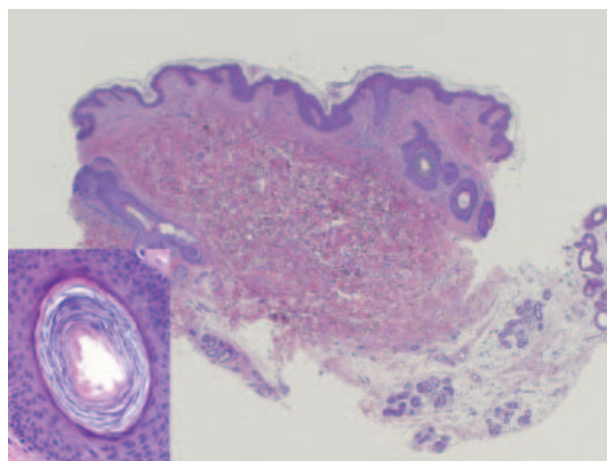


Figure 10. Biopsy 1 month after four treatments. Higher power of a miniaturized hair shaft in lower left corner.

non-dermatologists and non-physicians performing LHR. It is thought that at the present time, around the world most of these LHR procedures are performed by non-physicians. There are several laser and light-based devices in use for LHR and each one of them has its own advantages and disadvantages.

The exact mechanism of action of LHR is not fully understood but there are several theories. Melanin in the hair shaft and hair follicle is the target chromophore. The heat generated from the laser irradiation diffuses from hair shaft to hair follicle to peripheral stem cells.

It is imperative that the appropriate wavelength, pulse duration and fluence are used to achieve the best results from any laser/light treatment while minimizing possible side effects. A very high fluence and/or a very long pulse width can cause excessive heat damage which can lead to permanent scarring and pigmentary alteration (7). Most currently available LHR devices use a millisecond pulse width because the TRT of a hair follicle is 10–50 ms. The Nd:YAG is better suited for hair removal in individuals with dark skin because of its longer wavelength of 1064 nm. Most LHR devices are also used after application of a cooling gel or lotion and pre-cooling of skin is required to avoid epidermal damage, pigmentary changes and scarring.

This study was conducted to evaluate the safety and efficacy of a novel portable Nd:YAG laser with a short pulse of 0.65 ms without using a cooling method. This study shows that a microsecond (0.65 ms) pulsed Nd:YAG laser is at least as effective and safe as other bigger devices with longer pulse widths. Our results show that hair reduction was 84% and 82% 1 month after four monthly treatments and was 76% and 72% four months after four monthly treatments on high and low fluence areas respectively. The reduction from 84% to 76% and from 82% to

72% between 1 month and 4 months after the fourth treatment was also expected. In a recently published study, Khoury et al. showed that the axillary hair reduction went from 81.9% to 71.3% for the alexandrite laser, from 79.2% to 60.1% for the diode laser, from 61.8% to 48.2% for the Nd:YAG laser and from 80.3% to 68.1% for an alexandrite and Nd:YAG laser combination treatment from 1 to 2 months after three treatments (16). In our study, it was also noted that 1 and 4 months after the final treatment there was some reduction in hair on the 'control' sides as well (Table I). We attribute this phenomenon to the diffusion of energy from treatment side to control sides as they were close to each other. We chose to have the final evaluation 4 months after the final treatment because most LHR studies have a minimum of 3 months' follow-up because this is the duration of telogen hair for human axillary hair (6). The histologic evaluations of the biopsy specimen after treatment are similar to other published LHR studies. The US FDA also suggests that the follow-up should be between 4 and 12 months, depending on location on the body.

The current study is very comparable with the other published studies that used longer pulse durations and non-portable lasers for LHR. It shows that a short-pulsed Nd:YAG laser is as effective and safe as other devices used for LHR.

Conclusion

This well-controlled study shows that a 0.65 ms Nd:YAG laser is effective and safe for hair removal. This device has the advantage of being small and portable, and can be used without cooling and/or anesthetics. It is relatively inexpensive, affordable and is easy to move from office to office or room to room because of its small size.

Acknowledgement

This study was supported by an educational grant from Aerolase, Tarrytown, NY, USA.

References

1. Lepselter J, Elman M. Biological and clinical aspects in laser hair removal. *J Dermatol Treat.* 2004;15:72–83.
2. Lanigan SW. Management of unwanted hair in females. *Clin Exp Dermatol.* 2001; 26:644–7.
3. Food US, Drug Administration, CDRH Consumer Information. Laser facts. Hair removal. Updated 5/17/2002. URL: <http://www.fda.gov/cdrh/consumer/laserfacts.html>.
4. Grossman MC, Dierickx C, Farinelli W, Flotte T, Anderson RR. Damage to the hair follicles by normal-mode ruby laser pulses. *J Am Acad Dermatol.* 1996;35:889–94.
5. Altshuler GB, Anderson RR, Manstein D, Zenzie HH, Smirnov MZ. Extended theory of selective photothermolysis. *Lasers Surg Med.* 2001;29:416–32.
6. Dierickx C. Laser assisted hair removal: State of the art. *Dermatol Ther.* 2000;13:80–9.
7. Dawber RPR. Guidance for the management of hirsutism. *Curr Med Res Opin.* 2005;21:1227–34.
8. Anderson RR, Parrish JA. Selective photothermolysis: Precise microsurgery by selective absorption of pulsed radiation. *Science.* 1983;220:524–7.
9. Van Gemert MJC, Welch AJ. Time constants in thermal laser medicine. *Lasers Surg Med.* 1989;9:405–21.
10. Anderson RR. Laser-tissue interaction. In: Goldman MP, Fitzpatrick RC, editors. *Cutaneous laser surgery. The art and science of selective photothermolysis.* St Louis: Mosby-Year Book, 1994: 1–18.
11. Goldberg DJ, Silapunt S. Histologic evaluation of a millisecond Nd:YAG laser for hair removal. *Lasers Surg Med.* 2001;28:159–61.
12. Handrick C, Alster TS. Comparison of long-pulsed diode and long-pulsed alexandrite lasers for hair removal: A long-term clinical and histologic study. *Dermatol Surg.* 2001;27: 622–6.
13. McCoy S, Evans A, James C. Long-pulsed ruby laser for permanent hair reduction: Histological analysis after 3, 4 1/2, and 6 months. *Lasers Surg Med.* 2002;30:401–5.
14. Ono I, Tateshita T. Histopathological changes in the hair follicle after irradiation of long-pulse alexandrite laser equipped with a cooling device. *Eur J Dermatol.* 2000;10: 373–8.
15. Orringer JS, Hammerberg C, Lowe L, Kang S, Johnson TM, Hamilton T, et al. The effects of laser-mediated hair removal on immunohistochemical staining properties of hair follicles. *J Am Acad Dermatol.* 2006;55:402–7.
16. Khoury JG, Saluja R, Goldman M. Cooperative evaluation of long-pulse alexandrite and long-pulse Nd:YAG laser systems used individually and in combination for axillary hair removal. *Dermatol Surg.* 2008;34:665–71.