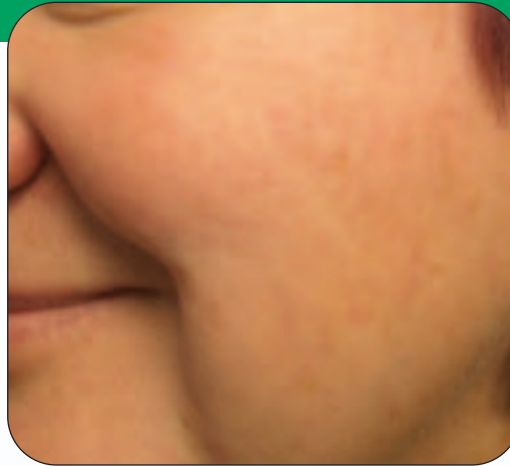
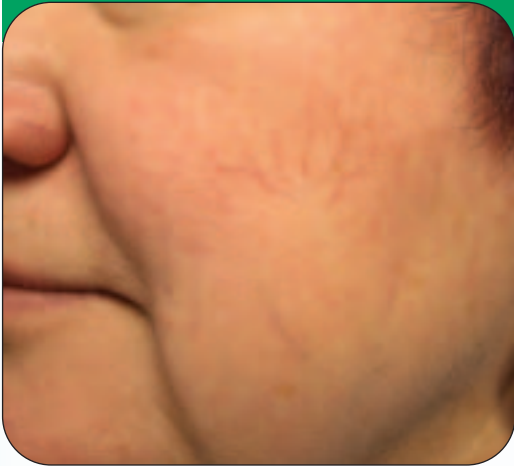
CLINICAL CASES

LightPod[®]Neo[™]

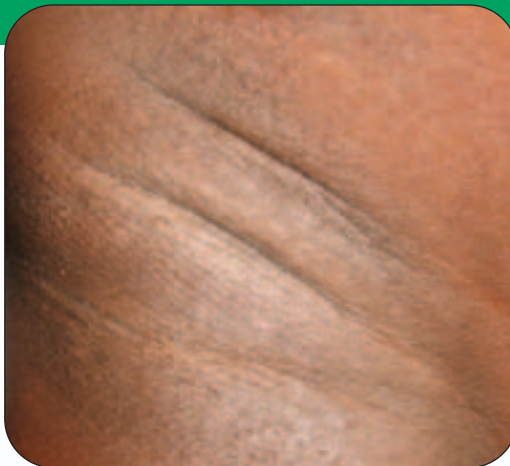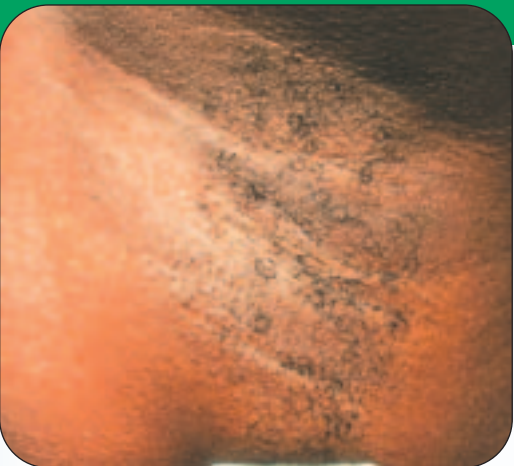Nd:YAG 1064nm Aesthetic Laser
with MicroPulse-1064[™] Technology



Telangiectasia Removal

(After two treatments)

Photos courtesy of
Edward Zimmerman, MD



Permanent Hair Reduction

(After three treatments)

Photos courtesy of
David Friedman, MD

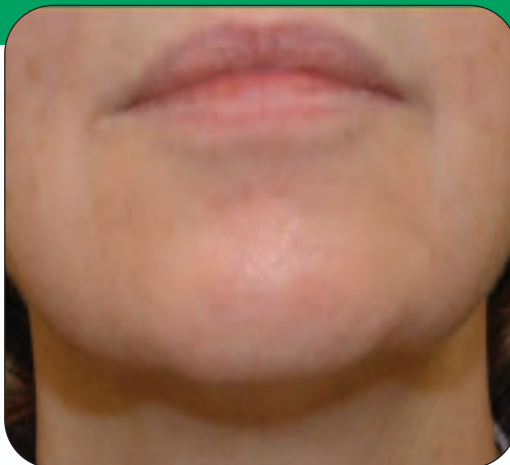
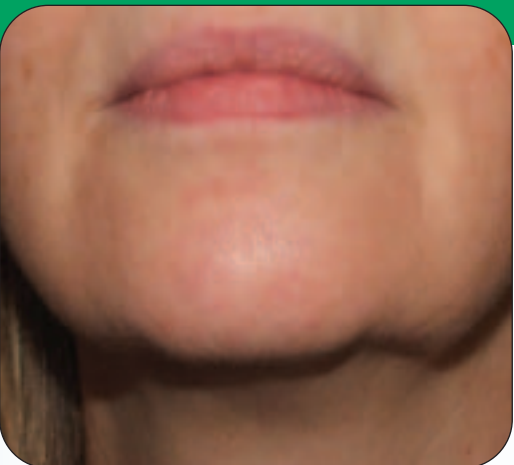
Photo- Rejuvenation with Skin Tightening

(After one treatment)

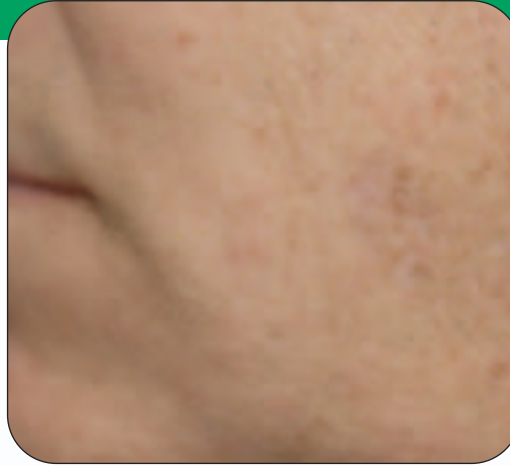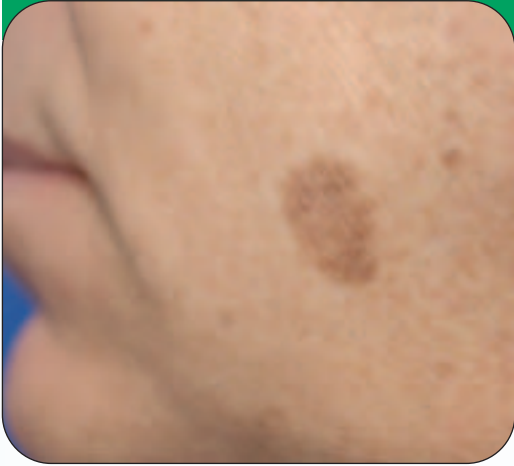Photos courtesy of
Aletha Tippett, MD

aerolase[®]
compact laser technology

CLINICAL CASES

LightPod[®]Neo[™]

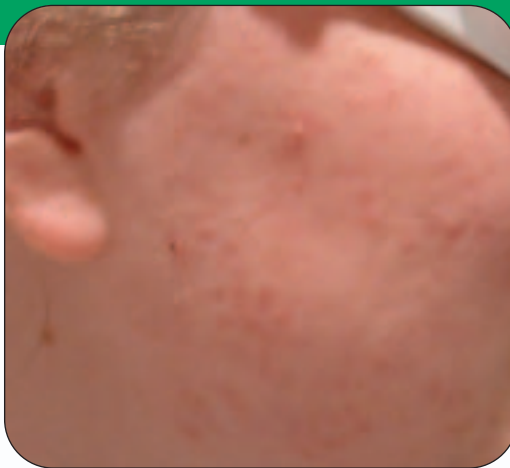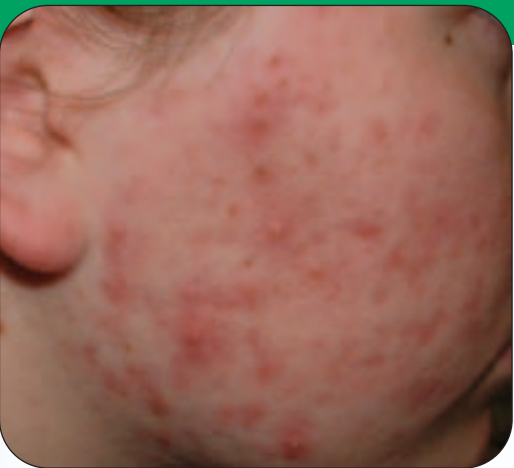Nd:YAG 1064nm Aesthetic Laser
with MicroPulse-1064[™] Technology



Pigmented Lesion Removal

(After two treatments)

Photos courtesy of
Edmund Liu, MD



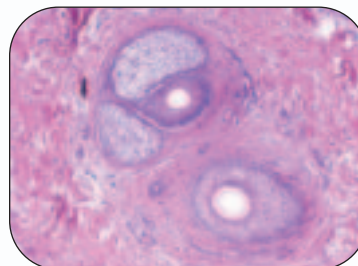
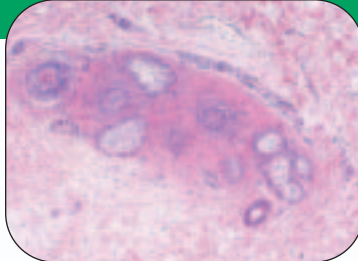
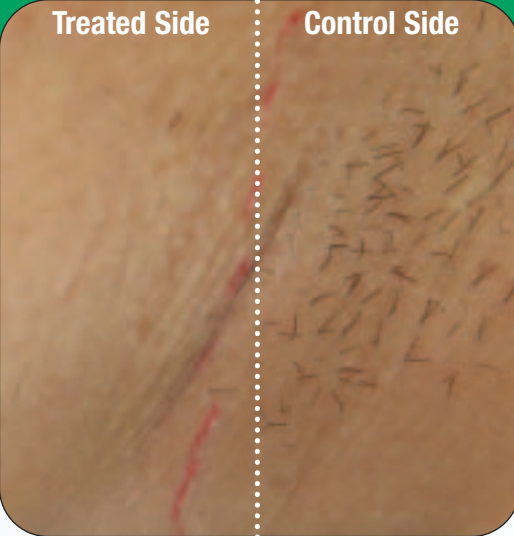Acne Clearance

(After three treatments)

Photos courtesy of
Aletha Tippett, MD

Treated Side

Control Side



Follicle counts showed 84% hair reduction after 4th Tx. Biopsies showed dense perifollicular fibrosis and mild perivascular lymphoplasmacytic infiltrate.

Permanent Hair Reduction

(After four treatments)

Photos courtesy of
Khalil Khatri, MD

aerolase[®]

compact laser technology