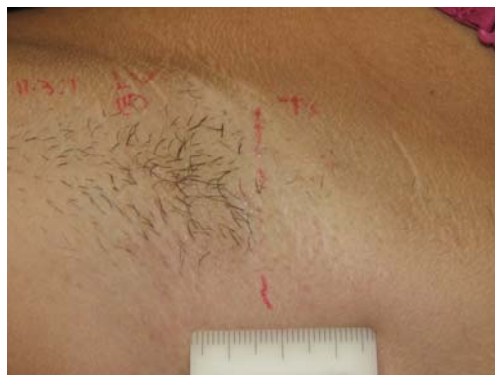
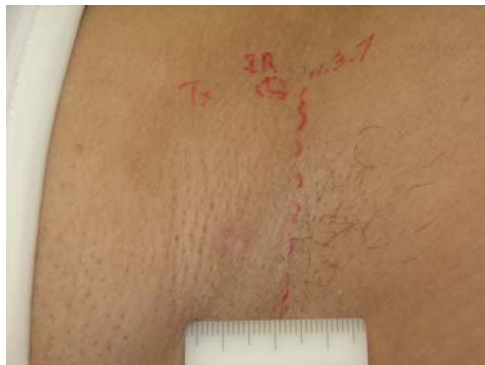
EFFICACY AND SAFETY OF A 0.65 msec PULSED PORTABLE Nd:YAG LASER FOR HAIR REMOVAL

Khalil A. Khatri, Beejul Khatri, Veronica Garcia, Skin & Laser Surgery Center of New England, Chelmsford, MA, Nashua, NH

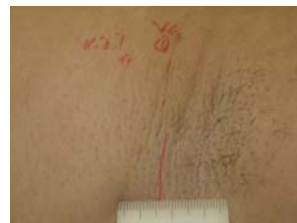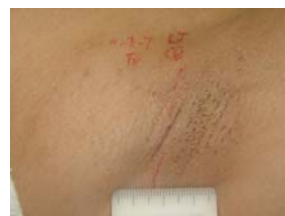Background and Objectives

Based upon the Thermal Relaxation Time of the hair shaft (3-30ms) or hair follicle (30-100ms), most lasers and light devices use relatively longer pulse widths for hair removal. This study was conducted to evaluate a shorter pulsed, 0.65ms Nd:YAG laser for hair removal.



Study Design and Methods

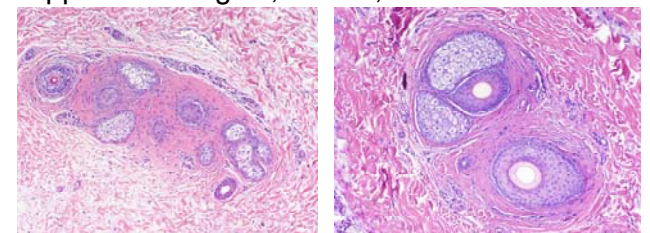
Six females with an average age of 31 and skin type III/IV were enrolled. Each axilla was divided in two halves. One half was treated and other was used as "control." Subjects were instructed not to shave one week before treatment and follow up visit. The treatment sites were treated either with a fluence of 21 or 36J/cm². Higher fluence was used with a focused 5mm spot and lower fluence was used with a collimated 6mm spot. No cooling, gel or lotion was used. An Nd:YAG laser, LightPod Neo™ (Aerolase, Tarrytown, NY) with a WL of 1064nm and a fixed pulse of 0.65ms was used. Hair counts were done before treatment and at each follow up visit. Subjects, investigators and independent observers graded the overall hair reduction on a scale of 1 to 5, where 1=no reduction, 2=<25%, 3=25-50%, 4=50-75% and 5=75-100%.



Results and Conclusions

Pain was "tolerable." One month after 4 monthly treatments, the hair reduction was graded as 5 (75-100%). The average hair count in the high fluence treated sites went from 114 to 18 (84% reduction) and in the low fluence areas from 135 to 24 (82% reduction). Biopsies showed a reduction in number of hair in the treated site. A shift to non-anagen hair cycle was noted along with dense perifollicular fibrosis and mild perivascular lymphoplasmacytic infiltrate. Fig. 1. Treated site showing many non-anagen hair and marked perifollicular fibrosis (10X), Fig. 2. Same patient's biopsy from an untreated site showing anagen hair shaft and minimal perifollicular fibrosis (10X).

This study shows that a 0.65ms Nd:YAG laser is effective and safe for permanent hair reduction. The treatment can be performed and is well tolerated without any cooling or application of gels, lotions, etc.



Khalil A. Khatri, M.D., skinlaser@aol.com

Financial grant, equipment, consulting fees, travel expenses, research grant, and honoraria from Aerolase